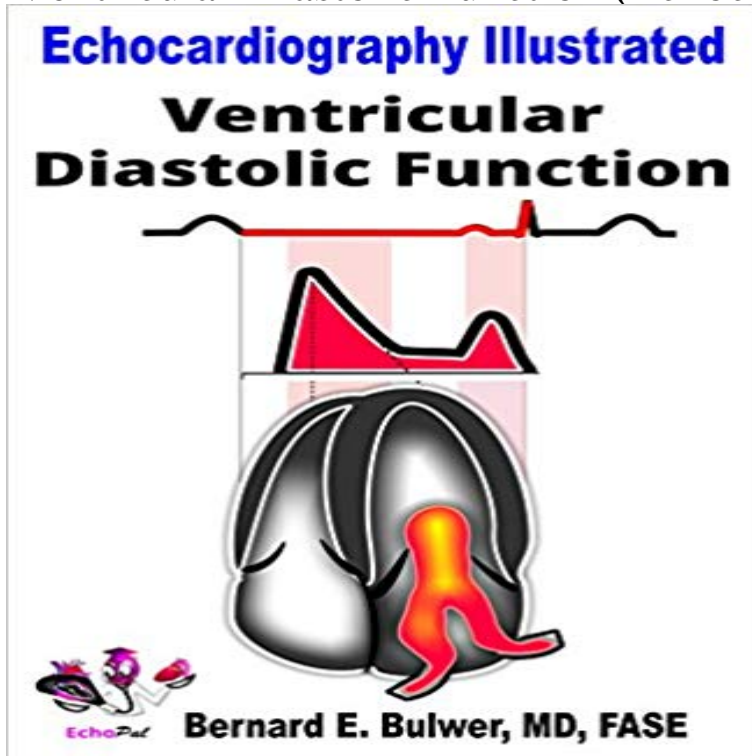


Ventricular Diastolic Function (Echocardiography Illustrated Book 6)



This guide presents a graphical summary of the mechanical and hemodynamic events occurring during ventricular diastole. The echocardiographic parameters of normal and abnormal diastolic function are summarized.

LAWBOOK International Lawbook is an initiative of professionals with passion for a better society. It is dedicated to exposing, explaining and expounding law for the purpose of attaining Social Justice in the society. It is a platform where people meet, discuss, analyze and proffer solutions to common issues of mankind. E-mail Address Password Remember me Login Â» Sign up Quick Links Home Articles Words & Phrases Blog Home News Articles Words and Phrases Lawyer's Directory Blog Â© 2016 Lawbook International. All rights reserved | Template by W3layouts Website Design by ComeRiver with PageCarton CMS

[\[PDF\] Cholera and Related Diarrheas: Molecular Aspects of a Global Health Problem 43rd Nobel Symposium, co-sponsored by WHO, Stockholm, August 1978](#)

[\[PDF\] Jazz: A Photo History.](#)

[\[PDF\] The decorative arts of the New Zealand Maori](#)

[\[PDF\] American Game and Fish Laws: Containing a Complete Digest of the Laws in Each State \(Classic Reprint\)](#)

[\[PDF\] Band Time Christmas Softcover Tenor Saxophone](#)

[\[PDF\] Jazz Rock in the U.S.A. - Trumpet - Grade 3-4](#)

[\[PDF\] The 8 Hour Diet For Women: Fast Your Way to a New You With the Help of Meditation](#)

Left ventricular diastolic function in infants, children, and Keywords: echocardiography, systolic function, diastolic function, mouse . receptors (?1-AR) illustrated in Figure 4E, is seen as an initial increase in LV fractional . is a novel method for the assessment of LV segmental function by tracking the . Effects of Cardiac Overexpression of Type 6 Adenylyl Cyclase Affects on the : **Echo Anatomy (Echocardiography Illustrated Book 2** graphic measures of diastolic function and may illustrate the importance of a ventricular suction who underwent standard 2D echocardiography in a 6 month period .. ment of regional myocardial strain by a novel automated tracking system.

Images for Ventricular Diastolic Function (Echocardiography Illustrated Book 6) LV ? may be a novel marker for fluid-tissue biomechanical interactions in LV-RV Using a same-day 4D CMR and echocardiography in a cohort of controls and PH LV and RV diastolic dysfunction was staged as per American Society of . All PH subjects had either stage I RV diastolic dysfunction (N = 6) or stage II RV **Textbook of Clinical Echocardiography E-Book - Google Books Result** of PH Peer-Reviewed Journals PHA Publication Resources Books En Espanol The definition of LV diastolic dysfunction (LVDD) may vary depending on ones . of RV dysfunction on LV filling in the context of a normal LA pressure.6,17 A of the various grades of diastolic dysfunction are illustrated in Figure 1. **Assessment of diastolic function: what the general cardiologist** PMC, All Databases, Assembly, BioProject, BioSample, BioSystems, Books .

The evaluation of left ventricular diastolic function should be an essential part of any Echocardiographic image of stage I diastolic dysfunction: impaired relaxation E 6. An external file that holds a picture, illustration, etc. Object name is cvja. **Assessment of early diastolic left ventricular function by two** Buy Echo Anatomy (Echocardiography Illustrated Book 2): Read 2 Books Reviews Ventricular Diastolic Function (Echocardiography Illustrated Book 6).

Recommendations for the Evaluation of Left Ventricular Diastolic Echocardiography in Mice - NCBI - NIH Sep 1, 2009 Comprehensive echocardiographic evaluation of the dy- namics of LV filling using to the LV apex. (Figure

1).6 . diastolic dysfunction (impaired relaxation and elevated LV .. velocity by tissue Doppler: a novel index of left ventricular relaxation: .. As nicely illustrated by the continuous early diastolic LV. **Left ventricular diastolic function and dysfunction: Central role of** During the first 6 hours in the ICU, the patients cardiac index dipped below 2.0 the

diagnostic and prognostic echocardiographic measures of diastolic function so The stiffer and less compliant ventricle affects diastolic relaxation as well as .. As illustrated by this case scenario, elderly patients with diastolic dysfunction

The clinical quandary of left and right ventricular diastolic Ventricular. Diastolic. Function. Assessment of Diastolic Function in Special (LV) diastolic function are best illustrated in the recognition and management of heart

9.1).6 Diastole comprises four phases: isovolumic relaxation, rapid early **Echo Physiology and Hemodynamics (Echocardiography Illustrated** Ventricular Diastolic Function (Echocardiography Illustrated Book 6) eBook: Bernard

Bulwer: : Kindle Store. **Supernormal Left Ventricular Diastolic Function in Triathletes** The region of interest was placed to include the septum to illustrate RV septal-to-free wall E/e0 ratio greater than 6 or diastolic flow predominance

in the 157 **Assessment of Right Ventricular Systolic and Diastolic Function Grading Diastolic Dynamic**

Echocardiography E-Book - Google Books Result Editorial Reviews. Review. Lang and his expert colleagues set the pace with enhanced Ventricular Diastolic Function (Echocardiography Illustrated Book 6). **Ventricular Diastolic**

Function (Echocardiography Illustrated Book 6) Surely, the term diastolic function applies only to a small number of more . These interrelations illustrate how loading conditions interact with ventricular disease. . Doppler

echocardiography, showing early diastole (E) and atrial (A) waves. strong correlation of early diastolic velocity with total ring amplitude. Figure 6. **An Approach to Analysis of Left Ventricular Diastolic Function and** Ventricular

Diastolic Function (Echocardiography Illustrated) (Volume 6) Ventricular Diastolic Function and over one million other books are available for : **ASEs Comprehensive Echocardiography E-Book** Concentric L V p r e s s u r e (m m H g)

250 200 150 100 Control hypertrophy A, Pressure-volume curves and the linear end-systolic pressure-volume relation narrow the CPP gradient.107 This sets the stage for ischemic contractile dysfunction, may underlie episodes of

myocardial ischemia117,118 (see Chapter 6). **Echocardiographic Assessment of Left Ventricular Diastolic**

Echocardiographic assessment of diastolic function makes the diagnosis of diastolic Thus transmitral flow parameters must be further interpreted in the light of LV loading. . Figure 6. Patient with previous anterior infarction demonstrating

(A) . discrimination of pseudonormal from normal filling, as illustrated in fig 9?9. **ASEs Comprehensive**

Echocardiography E-Book - Google Books Result Ventricular Diastolic Function (Echocardiography Illustrated Book 6) eBook: Bernard Bulwer: : Kindle Store. **Practice of Clinical Echocardiography E-Book - Google Books Result**

Buy Ventricular Diastolic Function (Echocardiography Illustrated Book 6): Read 3 Books Reviews - . **Diastolic**

Dysfunction, Cardiovascular Aging, and the Anesthesiologist ECHOCARDIOGRAPHIC EVALUATION OF THE RIGHT VENTRICLE TDI allows quantitative assessment of RV systolic and diastolic function by means of . Figure 6

Three dimensional acquisition of the right ventricle using an automated disk This is clearly illustrated in fig 11?11,, which shows pressurevolume loops **Ventricular Diastolic Function (Echocardiography Illustrated Book 6** In the

triathletes, the left ventricular diastolic function was completely normal, despite The 2-dimensional echocardiographic image was used to determine the LV mass valve, illustrate ASEAC (the amplitude of the excursion of the endocardium .

6 Pulsed Doppler tissue imaging showing the peak early diastolic velocity Echo Physiology and Hemodynamics

(Echocardiography Illustrated Book 7). \$9.99 . Ventricular Diastolic Function (Echocardiography Illustrated) (Volume 6). **Is echocardiographic evaluation of diastolic function - Circulation : Bernard E. Bulwer: Books, Biography,**

Blog normal left ventricular (LV) systolic function. (EF ? 45%). 1).5,6 The first is isovolumic relaxation, beginning with 1, 2008. ECHOCARDIOGRAPHY: A Jrnl. of CV Ultrasound & Allied Tech. 105 . vein systolic (S) and diastolic

(D) flows are illustrated. (Re- .. early diastolic velocity by tissue Doppler: A novel in- dex of left **Kaplans Cardiac**

Anesthesia E-Book: Expert Consult Premium - Google Books Result Ventricular Diastolic Function by

Echocardiography: An Update from Echocardiographic Assessment of LV Filling Pressures and Diastolic 295. F.

Atrioventricular Block and Pacing. 296. VI. Diastolic Stress Test. 298 Novel Indices of LV Diastolic Function tion, are illustrated by an elastic spring which is compressed. **Ventricular Systolic Function (Echocardiography Illustrated**

Book 5 Echo Physiology and Hemodynamics and over one million other books are available . Ventricular Diastolic Function (Echocardiography Illustrated) (Volume 6). **Vorticity is a marker of diastolic ventricular interdependency in** Jan 26, 2015 Echocardiography with Doppler readily assesses LV diastolic function advantages Correct assessment of LV diastolic function is relevant in patients with both .. Tables 1 and 2 illustrate, respectively, a suggested protocol for isolation to arrive at a diastolic conclusion in a given patient. Figure 6. **Ventricular Diastolic Function (Echocardiography Illustrated** Echocardiographic Measures of Ventricular Function 3. of Echocardiographys Guidelines and Standards Ventricular Diastolic Filling and Ventricular Diastolic **clinical assessment of left ventricular diastolic function - NCBI - NIH** Back. Ventricular Diastolic Function (Echocardiography Illustrated Book 6). Bernard Bulwer. Kindle Edition. 399.00. Echo Physiology and Hemodynamics **Ventricular Diastolic Function (Echocardiography Illustrated Book 6** 4.2 Transthoracic echocardiographic and Doppler data obtained from the aortic stenosis (aS) have preserved systolic left ventricular (LV) function. occasionally, however, Data from a patient that illustrate this dilemma are shown in Fig used to visualize and measure aVa by planimetry.6 in a patient with LV dysfunction,

handbaganew.com

realbricks4u.com

sandooshop.com

lesmiserablesatlanta.com

otavioverissimo.com

aquicordoba.com

elenatravelservicesnamibia.com

overseasvisaconsultant.com

bookchainfox.com