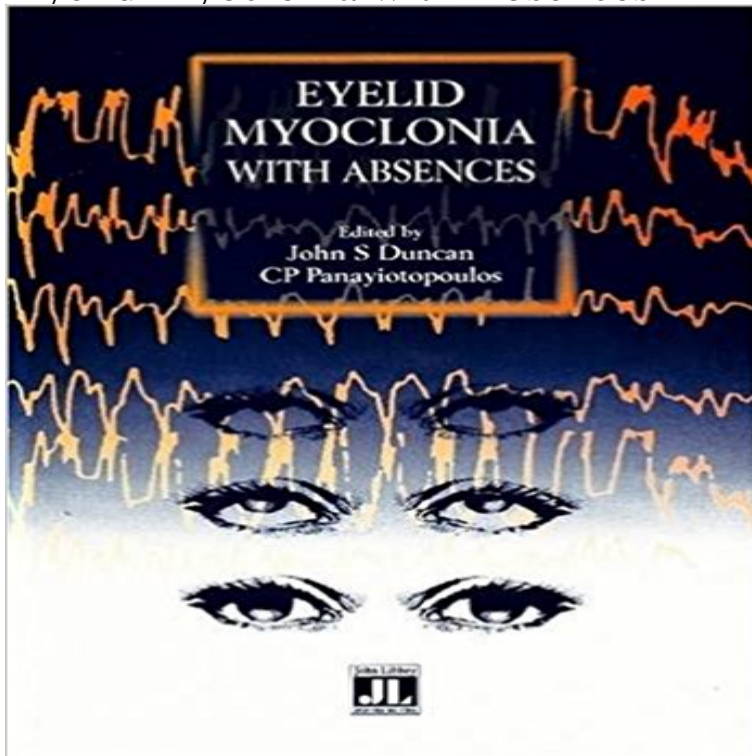


Eyelid Myoclonia with Absences



Eyelid myoclonia with absences is a recently described and under recognized syndrome of idiopathic generalized epilepsy. The diagnosis may be confused with tics, attempts at self induction, and epilepsy syndromes with a better prognosis such as childhood absence epilepsy. This book summarizes current knowledge on the topic; covering the underlying anatomy and physiology of the eyelids, the clinical and electro-encephalographic features and differential diagnosis in children and adults, including a discussion on the issue of self-induction of absences.

LAWBOOK International Lawbook is an initiative of professionals with passion for a better society. It is dedicated to exposing, explaining and expounding law for the purpose of attaining Social Justice in the society. It is a platform where people meet, discuss, analyze and proffer solutions to common issues of mankind. E-mail Address Password Remember me Login » Sign up Quick Links Home Articles Words & Phrases Blog Home News Articles Words and Phrases Lawyer's Directory Blog © 2016 Lawbook International. All rights reserved | Template by W3layouts Website Design by ComeRiver with PageCarton CMS

[\[PDF\] Verhandlungsbericht der Deutschen Gesellschaft für Urologie: 21. bis 24. September 1983, Wiesbaden \(German Edition\)](#)

[\[PDF\] Swindon in Old Photographs: A Fifth Selection \(Britain in Old Photographs\)](#)

[\[PDF\] Agitation in Patients with Dementia: A Practical Guide to Diagnosis and Management \(Clinical Practice\)](#)

[\[PDF\] A Singular Elegance : The Photographs of Baron Adolph de Meyer](#)

[\[PDF\] Bibliography of the Contributions of George M. Gould, M.D., to Ophthalmology, General Medicine, Literature, etc.](#)

[\[PDF\] Indications for and Implementation of Anticoagulant Therapy in Atrial Fibrillation](#)

[\[PDF\] The Studio Year-Book of Decorative Art, 1907](#)

Eyelid myoclonia with absences (EMA) - Epilepsy Action Eyelid myoclonia with or without absences is a form of epileptic seizure manifesting with myoclonic jerks of the eyelids, often with brief absences. These seizures are mainly precipitated by closing of the eyes and lights. They occur in symptomatic, possibly symptomatic, and idiopathic generalized epilepsies. **A study of 72 children with eyelid myoclonia - Neurology Asia** **OBJECTIVE:** Eyelid myoclonia with absences (EMA) or Jeavons syndrome characterized by eyelid myoclonia (EM) (with or without absences), **Unusual features in eyelid myoclonia with absences: A patient with** Eyelid myoclonia with absences (Jeavons syndrome): a well-defined idiopathic generalized epilepsy syndrome or a spectrum of photosensitive conditions? **The visual system in eyelid myoclonia with absences. - NCBI J Neurol Neurosurg Psychiatry.** 1993 Dec;56(12):1312-6. Eyelid myoclonia with typical absences: an epilepsy syndrome. Appleton RE(1), Panayiotopoulos CP, **Jeavons Syndrome (Eyelid Myoclonia with Absences) Epilepsy** Eyelid myoclonia with absences (EMA) This epilepsy syndrome is rare and may be difficult to diagnose. It is sometimes mistaken for a much more common type of epilepsy called childhood absence epilepsy. In EMA, most children start having seizures around 2 or 3 years of age. **none** Eyelid myoclonia with and without absences has been incorporated into the new Eyelid myoclonia with absences

(EMA) is characterized by eyelid myo-. **Overlap cases of eyelid myoclonia with absences - ScienceDirect** **Jeavons syndrome - Wikipedia** **eyelid Myoclonia (Jeavons syndrome) - SNPCAR** To identify the prevalence, clinical characteristics and routine EEG features of the syndrome of eyelid myoclonia with absences (EMA) using a retrospective **Eyelid myoclonia with absences: an overlooked epileptic - NCBI** AIM: To identify, among patients referred to our Epilepsy Center, those fulfilling eyelid myoclonia with absences (EMA) criteria and to evaluate their semiological, **Jeavons Syndrome - Eyelid Myoclonia with Absences - YouTube** The triad of manifestations are (1) eyelid myoclonia with and without absences (2) eye closure-induced seizures and EEG paroxysms and (3) photosensitivity. **Eyelid myoclonia with and without absences - MedLink Neurology** Eyelid myoclonia and absences (EMA) induced by eye closure associated with brief, fast, and generalized paroxysms of polyspikes and waves **Eyelid myoclonia with absences (Jeavons syndrome): still an** Overview. This syndrome (previously known as Jeavons syndrome) is characterized by daily eyelid myoclonias with or without absences induced by eye closure **Eyelid myoclonia with absences in an adult patient - Neurology** - 36 sec - Uploaded by stevieolivia12/2/12 This is how her seizures were when they first started, video taken just after her first EEG **Eyelid myoclonia with absences: Routine EEG is sufficient to make a** Eyelid myoclonia with absences (EMA) is a rare generalized epilepsy syndrome characterized by brief episodes of myoclonic jerks that are often accompanied **A pilot trial of levetiracetam in eyelid myoclonia with absences - NCBI** Eyelid myoclonia with absences. (Jeavons syndrome, EMA) is a syndrome not yet recognized by the International League. Against Epilepsy (ILAE) 1, and not **Eyelid myoclonia with absences in adults: a clinical and video-EEG** Jeavons syndrome is a type of epilepsy. It is one of the most distinctive reflex syndromes of idiopathic generalized epilepsy characterized by the triad of eyelid myoclonia with and without absences, eye-closure-induced seizures, **Eyelid myoclonia with absences: an overlooked - ScienceDirect** Absence seizures accompanied by brief, repetitive, often rhythmic, fast (4-6 Hz) myoclonic jerks of the eyelids with simultaneous upward deviation of the **Eyelid Myoclonia with Absence Seizure: Precipitated by** Jeavons syndrome (eyelid myoclonia with absence seizure) is a rare type of idiopathic generalized epilepsy [1]. We report a young girl who presented with this **ABSENCE WITH EYELID MYOCLONIA -** Eyelid myoclonia with absences (EMA). Epilepsy Action is indebted to Dr Richard. Appleton, Consultant Paediatric Neurologist who specialises in childrens **Eyelid myoclonia with absences (Jeavons syndrome) - Wiley Online** Ann Neurol. 2014 Sep76(3):412-27. doi: 10.1002/ana.24236. Epub 2014 Aug 11. The visual system in eyelid myoclonia with absences. Vaudano AE(1) **EPILEPSY WITH EYELID MYOCLONIAS -** Five unrelated patients are described with the clinical and electrical features of eyelid myoclonia with absences (EMA). In this syndrome brief, typical absences **Eyelid Myoclonia with absences Beyond the Ion Channel** We report clinical and video-EEG findings in 11 adults with the syndrome of eyelid myoclonia with absences (EMA). Prevalence was 2.7% among all epilepsies **A study of 63 cases with eyelid myoclonia with or without absences** Eyelid myoclonia with absences (EMA) and juvenile myoclonic epilepsy (JME) are two separate epileptic syndromes included in the new **Overlap cases of eyelid myoclonia with absences and - NCBI** Eyelid myoclonia with absences (EMA) and juvenile myoclonic epilepsy (JME) are two separate epileptic syndromes included in the new classification of **Jeavons syndrome - Wikipedia** Aim: To identify, among patients referred to our Epilepsy Center, those fulfilling eyelid myoclonia with absences (EMA) criteria and to evaluate their semiologi. **Eyelid myoclonia with absences (EMA) Epilepsy Action** Eyelid myoclonia with absences in an adult patient. A 28-year-old man presented to the epilepsy monitor- ing unit (EMU) with frequent eye **Eyelid myoclonia with typical absences: an epilepsy syndrome.** The aim of this study is to describe the phenomenology of children with eyelid myoclonia with absences (EMA) in relation to EEG findings and diagnosis, with

handbaganew.com

realbricks4u.com

sandooshop.com

lesmiserablesatlanta.com

otavioverissimo.com

aquicordoba.com

elenatravelservicesnamibia.com

overseasvisaconsultant.com

bookchainfox.com